

Foreign body in a Zenker's diverticulum (looking for the lost dentures)

Grzegorz Naprawa, Joanna Białkowska

Department of Internal Medicine, Specialist Hospital, Szczecin-Zdunowo, Poland

Prz Gastroenterol 2014; 9 (4): 254–258
DOI: 10.5114/pg.2014.45109

Key words: Zenker's diverticulum, cricopharyngeal diverticulum, foreign body.

Address for correspondence: Grzegorz Naprawa MD, Department of Internal Medicine, Specialist Hospital, 11 Sokółowskiego St, 70-891-Szczecin, Poland, phone/fax: +48 914 427 369, e-mail: grzen@op.pl

Abstract

Zenker's diverticulum (ZD), an acquired false pharyngoesophageal diverticulum, is a rare pathology. The prevalence of ZD among the general population is believed to be between 0.01% and 0.11%. Most patients are elderly men with symptoms of dysphagia. The most common treatments are open surgical diverticulectomy with or without cricopharyngeal myotomy and endoscopic myotomy. The authors report the case of a dental prosthesis lodged within an asymptomatic ZD in a 73-year-old man. It was safely removed endoscopically. So far, there have only been single reports of entrapment of an enteroscopy capsule lodged in a ZD in medical literature.

Introduction

Zenker's diverticulum (ZD) occurs rarely. Its prevalence is estimated to be 0.01–0.1% in the general population [1]. It is also known as pharyngoesophageal diverticulum or hypopharyngeal diverticulum. It is an acquired pseudodiverticulum of the upper digestive tract. It is localised proximally in relation to the upper oesophageal sphincter, usually on the posterior pharyngeal wall, on the left side of the neck. The development of the diverticulum is explained by impaired coordination between the inferior constrictor muscle and the cricopharyngeus muscle. It occurs in the so-called Killian's triangle, a potential area of muscle weakness between oblique fibres of the inferior constrictor muscle and transverse fibres of the cricopharyngeus muscle. The disease may remain asymptomatic for weeks or years. In the symptomatic form it manifests as dysphagia. Diagnosis can be set based on barium oesophagram and panendoscopy. The management of choice, for the symptomatic form, is surgical or endoscopic treatment. The authors present a rare case of foreign body incarceration – in this case, dentures in ZD – which was endoscopically removed without complications. In the available literature there are only isolated reports of an endoscopic capsule incarcerated in the diverticulum.

Case report

A 73-year-old patient, a professor of medicine, admitted himself to the Endoscopy Unit of the Specialist Hospital, Szczecin-Zdunowo to perform panendoscopy because of a suspected foreign body in ZD. Having woken up, the patient realised his denture was missing (of one tooth). He did not find it in his surroundings, which led to suspicion of swallowing. Neck and chest radiograph, performed on the patient's request, revealed on the first thoracic vertebra level, a triangle-shaped shadow with measurements 1.1 cm × 1.3 cm, intensely absorbing X-rays, which could correspond to the tooth (Figure 1). After oral contrast administration, oesophageal ZD was revealed, filled with contrast medium, with measurements 2.7 cm × 2.0 cm (Figure 2). The patient suffered from arterial hypertension, arrhythmia, and chronic coronary heart disease in the form of a previous myocardial infarction, chronically treated with *inter alia* angiotensin-converting-enzyme inhibitors and β -blockers. Hoarseness and solid-food dysphagia had occurred periodically since June 2009. The symptoms did not cause a significant weight reduction nor had a relevant impact on daily functioning, and the patient linked them with heart disease and pharmacotherapy and was unaware of the occurrence of the diverticulum. In an endoscopic study (performed on the patient's re-

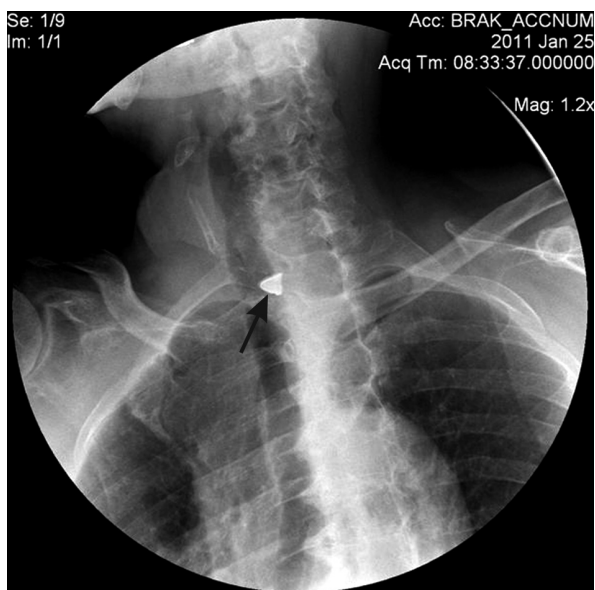


Figure 1. Plain cervical study. Triangular shape of the shadow (arrow) at the level of the first thoracic vertebra (Th1)

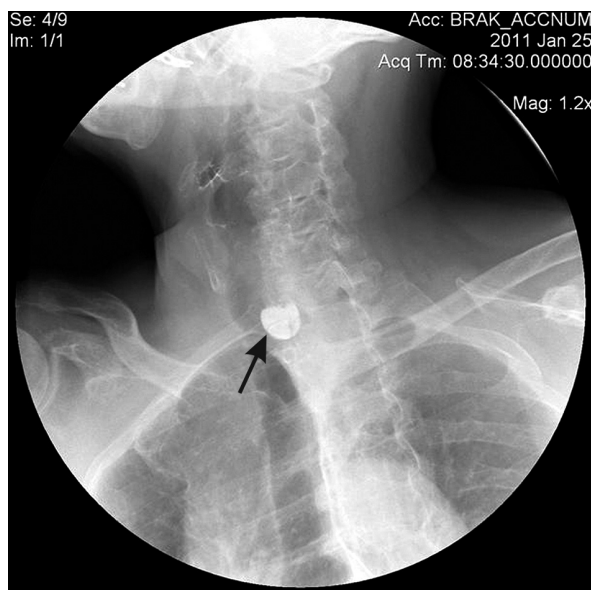

Figure 2. Oesophageal barium study demonstrating a 2-cm Zenker's diverticulum (arrow) at the level of Th1, filled with contrast medium

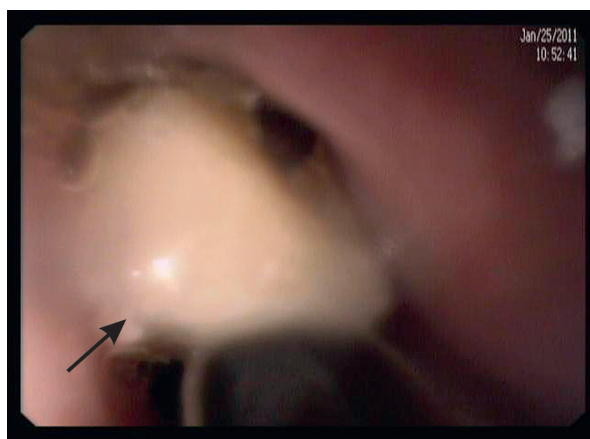


Figure 3. Endoscopic view of a single-tooth prosthesis (arrow) lodged in the Zenker's diverticulum

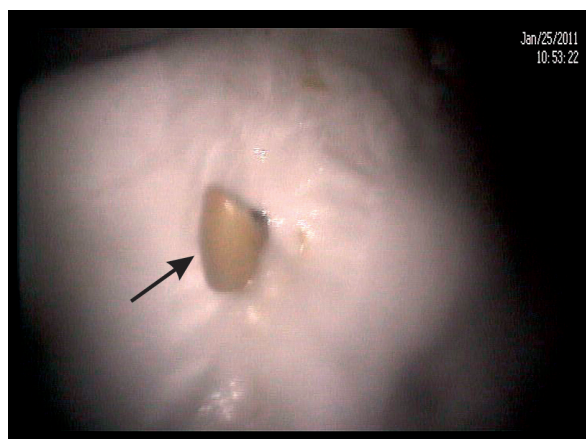

Figure 4. View of the removed prosthesis (arrow)

quest with no premedication) a small ZD and a foreign body present in its lumen were revealed: a single-tooth denture (Figure 3). A successful attempt to remove it using a Dormia basket was carried out (Figure 4). The course of the procedure was without complication. During the following 6-month follow-up the patient has not suffered from aggravation of symptoms and has not decided on definite treatment yet.

Discussion

Zenker's diverticulum was first reported by Ludlow in 1769 [1–7] and Friedrich von Zenker in 1878 (his sur-

name gave its name to the diverticulum). It is defined as an acquired pseudodiverticulum of the upper digestive tract because its wall is built of mucosa and submucosal. It can be likened to a hernia through the muscle membrane. It occurs rarely. Its prevalence is estimated to be 0.01–0.1% of the population. In Great Britain two cases in 100 thousand people are reported yearly. Its actual prevalence is hard to estimate because of its usual asymptomatic course. In 2% of patients with ZD, it has occurred in other family members [8]. It occurs in men more often than in women (1.5 : 1 M : F), in advanced age (7th–8th decade of life), and rarely in people below

40 years of age [1, 4, 8]. It is reported more often in Northern Europe, the USA, Canada, and Australia [1]. Zenker's diverticulum is localised proximally in relation to the upper oesophageal sphincter, usually on the posterior pharyngeal wall, on the left side of the neck. In the early 1990s precise recognition of the pathogenesis of this disease was related to the development of oesophageal manometry. A number of concepts related to structural and physiological abnormalities of the cricopharyngeus muscle have been raised over the years. Zenker's diverticulum appears in an area of muscle weakness between oblique fibres of the inferior constrictor muscle and transverse fibres of the cricopharyngeus muscle (so-called Killian's triangle), with co-existing impaired coordination between the constrictor muscle and the cricopharyngeus muscle. The reason for the above-mentioned phenomenon is fibrosis of the cricopharyngeus muscle and the proximal part of the oesophagus consisting of striated muscle. Inferior constrictor muscle contraction and lack of relaxation of the cricopharyngeus muscle lead to abnormal passage of food. As a result, in the sublaryngeal portion of the oesophagus, increased intraoesophageal pressure causes herniation of mucosa and submucosa through Killian's triangle. In histopathological study the presence of inflammatory cells and fibrosis features of the cricopharyngeus muscle are detected. Zenker's diverticulum coincides with other pathologies of the oesophagus, such as oesophageal web (as many as 50% of cases), hiatus hernia, gastrooesophageal reflux, achalasia, and polyps [4]. The course of the disease may remain asymptomatic for weeks or years. Clinical manifestation depends on the size of the diverticulum. Brombart divided it into four stages depending on its length and visibility in relation to the contraction and relaxation phases of the upper oesophageal sphincter (UES). In the first stage, a diverticulum of 2–3 mm resembles the shape of a 'thorn' and is visible only when the UES contracts. In the second stage, 7–8 mm, it forms the shape of a 'club', and also only shows only during UES contraction. In the third stage, the diverticulum measures usually more than 1 cm, resembles a 'pouch', and is visible in both phases. In the last stage it additionally causes pressure on the oesophagus [5]. Its clinical manifestation may be poorly expressed (foreign body sensation in the throat, or throat irritation with a considerable amount of mucous secretion) or more turbulent (undigested food and mucus regurgitation, dysphagia in early phase of deglutition in 80–90% of cases, chronic cough in 30–40% of cases, hoarseness and halitosis, neck tumour presence in physical examination, significant weight loss and food aspiration into the airways) [1, 4]. Diagnosis of ZD is based on imaging studies:

contrast study of the upper digestive tract and panendoscopy. Lateral or oblique projection radiograph may reveal a diverticulum of different size usually localised midline, directed downwards and to the left side of the body. Panendoscopy, because of possible assessment of mucosa and drawing specimens for histopathological study, allows the diagnosis of possible coinciding abnormalities in the diverticulum. Lining mucosa may be a source of bleeding, and ulceration may be formed within, and even squamous cell carcinoma (0.4–1.5%) [1]. Zenker's diverticulum may be a location for foreign body incarceration, bezoar formation, and the cause of vocal-fold paralysis and fistula formation (tracheoesophageal fistula or towards the prevertebral ligament with myelitis).

In cases of severe symptoms or the development of complications, the management of choice is surgical or endoscopic treatment. The first attempts at diverticulum treatment were reported by Bell in 1816. They involved a fistula formation between the skin and pouch [6]. Currently, in the early stage of disease, endoscopic diverticulotomy is recommended. It is often the only hope for patients in advanced age with numerous coinciding diseases, of high perioperative risk. It was first reported by Mosher in 1917 [3, 4, 6]. In 1960 Dolman and Mattson presented an endoscopic technique of septum division between the diverticulum and the oesophagus using electrocoagulation [3, 4–6], while in 1984 Overbeek *et al.* used a laser to do so. In 1993 Collard *et al.* used a stapler to cut a muscular septum [3–6]. Unfortunately this method involves the application of general anaesthesia. Furthermore, the risk of small herniation of the oesophagus remains because of probable incomplete myotomy. Antibiotic prophylaxis is recommended prior to endoscopic diverticulotomy (i.e. 2nd generation cephalosporin). The procedure is performed with analgesation and lidocain local anaesthesia. It involves division of the muscle septum between the diverticulum and the oesophagus. A semi-rigid catheter (12 Fr) or thin Savary type dilatator (6–7 mm) is introduced into the oesophagus over the guidewire to improve access to the septum and to protect the opposite oesophageal wall against thermal injury. Division with the use of a direct-current monopolar needle knife usually starts in the middle section at the top of the septum and ends at its base. Division can be also done with the use of an argon plasma coagulation (APC) beamer with recommended diathermy settings ERBE 200 ICC 120/A60; 1.2 l/min [9]. To improve the safety of the procedure, especially upon longer needle knife incisions, some experts recommend clipping of the edges (to prevent inter alia spontaneous expansion of the incision line). Another way to improve safety and effectiveness of

treatment is to use a diverticuloscope [10]. The choice of procedure technique depends on the endoscopist's experience and preference. The objective is to reduce the length of septum to below 1 cm, which allows the diverticulum to be emptied of residual ingesta.

During one session an incision of 1.5–2.0 cm is made, sufficient to cure a small diverticulum. For diverticula longer than 3 cm the procedure may need to be repeated at an interval of 2 days to 3 months. The procedure can be carried out in ambulatory care. Endoscopic diverticulotomy is an effective treatment method. It leads to withdrawal of symptoms in 85% of cases [11]. Common complications include subcutaneous and mediastinal emphysema (up to 23%) and a remaining small pouch in the diverticulum floor and residual septum. Rarely observed complications include bleeding (up to 10%), which withdraws either spontaneously or after endoscopic treatment, pharyngeal stenosis, septum recurrence (18–20%), mediastinitis and fistula [1, 4, 11]. Risk of death is estimated to be 0.2% [3].

To minimise bleeding risk it is recommended that incision margins be closed with the use of a stapler or application of metal clips [4]. In the advanced stage of the disease the management of choice is surgical treatment. The traditional technique is performed from cervical access and involves diverticulum resection with cricopharyngeal myotomy. Furthermore, it is possible to perform either diverticulopexy or myotomy alone. The first surgical treatment of a diverticulum was performed in 1877 [7]. Currently it is a one-stage procedure. In order to avoid too wide a resection, and following stenosis, it is performed with oesophagus intubation and the introduction of an endoscope inside the pouch. The side effects of surgical treatment include, inter alia, pharyngocutaneous fistula formation, mediastinitis, larynx muscles paralysis, symptoms recurrence, and death (1.6%) [3, 4].

Zenker's diverticulum should be differentiated from all diseases that present with upper dysphagia, i.e. laryngocele, oesophageal myoma, polymyositis, oesophageal web, gastroesophageal reflux, hiatus hernia, stenosis of the upper portion of the oesophagus, and carotid body tumour. As a result of progressive disease character it is preferred to treat all symptomatic patients. Due to the fact that ZD typically concerns patients in advanced age, often with numerous coinciding illnesses, it is highly probable that endoscopy will be a treatment option of choice in the future.

Discussing the above-mentioned clinical case, we would like to emphasise that despite the rare occurrence of ZD, it should be considered in differential diagnosis of dysphagia. Early phase deglutition abnormalities along with difficult oesophagus intubation during

panendoscopy may indicate the presence of ZD. It may press on the oesophagus and, as a result, an attempted intubation endoscope is introduced inside its lumen instead of into the oesophagus that is at risk of perforation. In all cases the endoscope must be introduced under visual control and without use of pressure. In case of difficulties, the study should be terminated. Studies with the use of lateral optics (duodenoscopy, echo-endoscopy) require special care.

Conclusions

It must not be forgotten that the diverticulum may be a location for foreign body incarceration in the digestive tract, as in the presented case. In this case, its immediate endoscopic removal prevented the patient from developing complications (risk of diverticulitis, perforation, aspiration into airways) and prevented the need for surgical treatment. Endoscopic capsule incarceration in ZD lumen have been reported, which must be taken into consideration when referring elderly patients or those with an unknown cause of dysphagia. Due to the risk of endoscopic capsule incarceration, patients with symptomatic or large diverticulum should not undergo this procedure. This issue, however, may be avoided by releasing the capsule directly into the stomach, under endoscopic control, with the use of an overtube [12].

References

1. Ferreira LE, Simmons DT, Baron TH. Zenker's diverticula: pathophysiology, clinical presentation, and flexible endoscopic management. *Dis Esophagus* 2008; 21: 1-8.
2. Odemis B, Ataseven H, Basar O, et al. Ulcer in the basis of Zenker's diverticulum mimicking esophageal malignancy. *J Natl Med Assoc* 2006; 98: 1177-9.
3. Visosky AM, Parke RB, Donovan DT. Endoscopic management of Zenker's diverticulum: factors predictive of success or failure. *Ann Otol Rhinol Laryngol* 2008; 117: 531-7.
4. Ginsberg GG, Kochman LM, Horton I, et al. Clinical gastrointestinal endoscopy [Polish]. *MediPage*, Warsaw 2009.
5. Stemerman DH, Mercader V, Kramer G, et al. An unusual presentation of Zenker's diverticulum. *Clin Imaging* 1996; 20: 112-4.
6. Bloom JD, Bleier BS, Mirza N, et al. Factors predicting endoscopic exposure of Zenker's diverticulum. *Ann Otol Rhinol Laryngol* 2010; 119: 736-41.
7. Arunachalam PS, Cameron DS. Persistent foreign body sensation and pharyngeal pain due to retention of staples: an interesting sequelae of endoscopic stapling procedure. *J Laryngol Otol* 2001; 115: 425-7.
8. Klockars T, Sihvo E, Makitie A. Familiar Zenker's diverticulum. *Acta Otolaryngol* 2008; 128: 1034-6.
9. Mulder CJ, Costamagna G, Sakai P. Zenker's diverticulum: treatment using flexible endoscope. *Endoscopy* 2001; 33: 991-7.
10. Costamagna G, Iacopini F, Tingali A. Flexible endoscopic Zenker's diverticulotomy: cap-assisted technique vs. diverticuloscope-assisted technique. *Endoscopy* 2007; 39: 146-52.

11. Case DJ, Baron TH. Flexible endoscopic management of Zenker diverticulum: the Mayo clinic experience. *Mayo Clin Proc* 2010; 85: 719-22.
12. Simmons TD, Baron TH. Endoscopic retrieval of a capsule endoscope from a Zenker's diverticulum. *Dis Esophagus* 2005; 18: 338-9.

Received: 18.11.2011

Accepted: 1.07.2012